

Original article:

Interdisciplinary management of Impacted teeth in an adult with Orthodontics & Free Gingival graft : A Case Report

Dr Renuka Patel, Dr Falguni Mehta, Dr. Ashish Pandey

Assistant Professor, Dept. Of Orthodontics , Government Dental College & Hospital, Ahmedabad

Professor & HOD, Dept. Of Orthodontics , Government Dental College & Hospital, Ahmedabad

Part III PG, Dept Of Orthodontics , Government Dental College & Hospital, Ahmedabad

Corresponding author: Dr. Renuka Patel

Abstract:

This is a case report describing the combined mechanotherapy treatment of a 18 year old male with impacted maxillary incisor & canine (Class III impaction), over retained deciduous central incisor & canine, erupted conical shaped supernumerary teeth palatal to it, maxillary lateral incisor was proclined, Considering the golden principle of conserving the natural teeth and avoidance of future pathologies relating to the untreated impacted teeth such as root resorption of the adjacent teeth, migration of neighbouring teeth, loss of arch length, internal resorption of impacted tooth, ankylosis, dentigerous cyst formation & periodontal pockets etc. & to relieve psychological stress, First phase treatment involves extraction of over-retained deciduous and supernumerary teeth followed by full thickness mucoperiosteal flap surgical exposure with closed technique for orthodontic eruption of impacted teeth with Begg's technique and 0.022 slot MBT Pre-adjusted edgewise appliance. Miller's Class III gingival recession was observed in relation to maxillary left central incisor after alignment but not seen in maxillary left canine. Second phase with periodontal treatment which involved free gingival graft for recession coverage. Gingival architecture of impacted teeth depends on type, depth, level, angulation of impaction and amount of overlying bone rather than bonding attachment on labial or palatal surface. Alignment and levelling of maxillary impacted central incisor & canine to the occlusal table & assimilated in the dental arch, to provide esthetically pleasant smile, to prevent the prosthetic replacement.

Key words : Impacted teeth, Orthodontic eruption, Free gingival graft.

Introduction:

Management of impacted teeth presents a major & common challenge to orthodontist. And it depends entirely upon the severity of the problem & age at which it present for treatment, proper diagnosis, level of impaction, inclination & depth of impaction, amount of root formation, type of exposure, amount of bone removed, type of attachment, orthodontic attachment etc. numerous orthodontic techniques & appliances have been introduced to treat the same. In this case report, we describe the treatment of a 18 yrs old male by combination mechanotherapy of Begg's and PEA appliance by interdisciplinary approach.

First phase treatment involves extraction of over-retained deciduous, supernumerary teeth followed by surgical exposure with closed eruption technique (full thickness mucoperiosteal flap along with tunnel traction) for impacted maxillary central incisor & canine on left side. A new balanced & stable occlusion was achieved after treatment when the treatment includes Begg's appliance, Pre-adjusted edgewise appliance & Periodontal surgery (free gingival graft for recession coverage).

Management of impacted teeth in the orthodontic practice is of paramount importance, as the existence of one or more impacted teeth may complicate the orthodontic treatment & it varies widely from extraction of the tooth to closed or open orthodontic eruption.

Diagnosis:

The patient was a 18 yrs old male with a chief complaint of irregularly placed upper front teeth. No positive medical or dental history was present. The pre-treatment facial photograph showed symmetric face with competent lips, straight profile, deepmentolabial sulcus, acute nasolabial angle, non-consonant smile arc. Radiographic findings revealed impacted horizontal mesioangular maxillary central incisor & canine, erupted supernumerary teeth palatally to upper left deciduous central incisor, upper left lateral incisor is deflected labially& tipped distally because of pressure of impacted upper left canine.

Clinical Examination:

- Over retained deciduous central incisor & canine
- Conical shaped two supernumary teeth erupted palatally
- Maxillary lateral incisor is tilted labially& distally
- A slight palatal deformation is firm to palpation

Radiographic Examination:

OPG depicts the axial inclination of the central incisor & canine's long axis, the displacement of its crown toward the mid-sagittal plane, both lies in close proximity & superior to the mucogingival line of the lateral incisor, drifted on a horizontal plane, located superior to the roots of incisors and premolars which suggest deep bony impaction. Occlusal view shows the horizontal orientation of central incisorand canine in bucco-lingual position. Radiographic findings revealed deep infrabonyhorizontal impaction of central incisor (Class 3 impaction)& canine became transposed with lateral incisor which caused migration of the lateral incisor crown distally.

Treatment Objective:

For deep bony impaction of central incisor & canine lying horizontally over the roots of the incisors

1. Change the eruptive inclination of the canine & central incisor making that the teeth do not emerge palatally.
2. Guide their crowns into the lingual trajectory to correct their path of eruption
3. To ensure reconstruction of the periodontal margins of the incisors & canine.
4. Eliminate dental crowding in the upper arch, level & align the teeth.
5. Obtain ideal overjet& overbite
6. Create a stable functional occlusion.
7. Maintain Class I Molar relation on both sides.
8. Achieving a pleasant smile & soft tissue profile.

Treatment Progress:

Orthodontic & Surgical Treatment Progress:

- Extraction of deciduous central incisor,canine & two supernumary teeth.
- Opening space in the dental arch
- Preparing anchorage on the buccal side & active unit to move the impacted teeth in desired position.

- Begg's appliance is bonded in maxillary arch because there was deep infrabony Class III impaction of central incisor & canine, proclined lateral incisor. So in this case to reinforce anchorage & minimize the migration of adjacent teeth in the available space for orthodontic eruption.
- Surgical (approach) intervention from a labial & palatal aspect & a section of mucosa has been retracted to uncover the palatal surface of impacted central incisor & Canine & bond a Begg's bondable bracket to the palatal surface of Central Incisor & Canine with a metallic 0.009" ligature wire is affixed. Consolidate the arch with the ligature wire below the base A/W 0.018" Special Plus with circle hook at the mesial of central incisor on right side & mesial of first and second premolar, along with 0.016" piggy back NiTi to which ligature wire force applied from the attachment on the palatal surface of Central Incisor & Canine which creates a pure vertical eruption.
- Moved the Canine distally using 0.018" base A/W with circle hook, E-chain is stretched from canine and 1st premolar and vertical force is continued with 0.009" wire to piggy back 0.016" NiTi.
- As soon as Maxillary left central incisor & left canine were visible in the oral cavity to the gingival crest, sectional 0.018" base A/W with a circle placed mesial to the 1st premolar & molar at the same horizontal level as the canine. E-chain is stretched from it to the canine. It moves the canine crown away from the lateral incisor.
- After 26 months of orthodontic treatment, Millers Class III recession was observed in relation to maxillary left central incisor for which free gingival graft for recession coverage was undertaken. But same problem of gingival recession was not encountered with maxillary left canine.

Treatment Results:

The teeth are well aligned & levelled after orthodontic treatment. The first molars were in an Angles Class I relationship with ideal overjet, overbite & good interdigitation. The soft tissue were in harmonious relationship with pleasant smile. The Post treatment photographs showed that maxillary & mandibular anteriors were well aligned. Normal occlusion and gingival architecture with pleasant smile achieved by orthodontic and periodontal intervention. Root parallelism was achieved & no marked root resorption was detected.

Discussion:

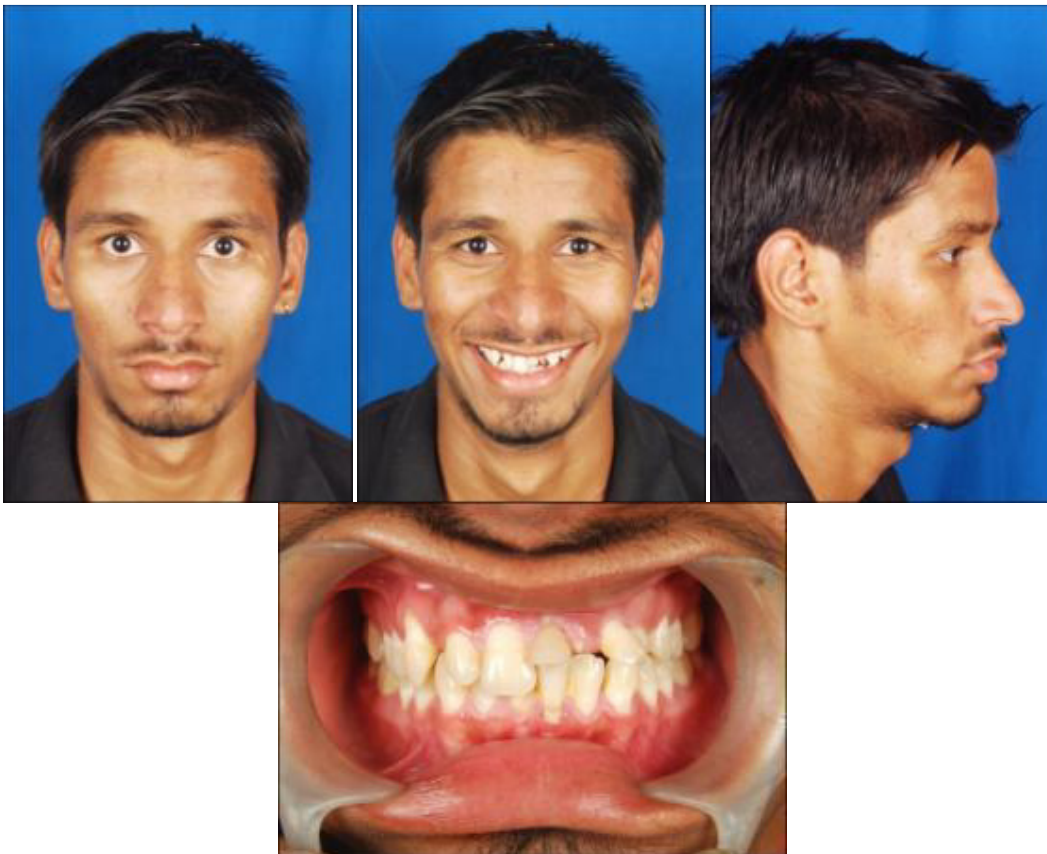When using the fixed appliances, one should be cautious about reinforcing anchorage to prevent unfavourable effects such as tight ligation, rigid tie-backs of arches, cinchback of the archwires etc. Among the fixed appliances available, Begg's Technique has long been proved to be one of the best treatment modality for impacted teeth with minimum anchorage loss followed by Pre-adjusted edgewise technique.

Modified ribbon arch bracket with vertical slot without in built tip, torque & rotational control provides better anchorage control as well as for encroachment of space because of tipping of adjacent teeth. When there is palatal impaction of the central incisor & canine, the attachment is bonded to the palatal surface of the tooth & the ligature is twisted around the attachment. The enamel must be in contact with gingiva to ensure an immediate adhesion so that when extrusive force is applied, gingiva will correctly accompany the emerging tooth. For canine, after horizontal displacement is corrected, the piggy back 0.016" NiTi with 0.018 Special plus base archwires used to extrude the tooth. Another benefit derived from first moving impacted teeth horizontally is that can avoid having cuspal interference. But for central incisor extrusive movement with Begg's Technique followed by rotational correction with 0.022 MBT slot PEA appliance, in which apically displaced gingival tissue remain apically.

The force vector applied coronally&lingually. A heavy base archwire with piggy back NiTi& E-chain moves the impacted tooth towards the gingival crest & tilt it into a normal path of eruption. The correction was achieved by a combination of Begg's, Pre-adjusted edgewise technique in 26 months but Millers Class III gingival recession was observed in Maxillary left Central Incisor after alignment in the arch for which Periodontal intervention with free gingival graft was planned after 6 weeks of active orthodontic treatment. Wrap-around retainer in upper archand Hawley's retainer in lower arch was given and after 2 months of retention periodontal intervention with free gingival graft for recession coverage was undertaken.

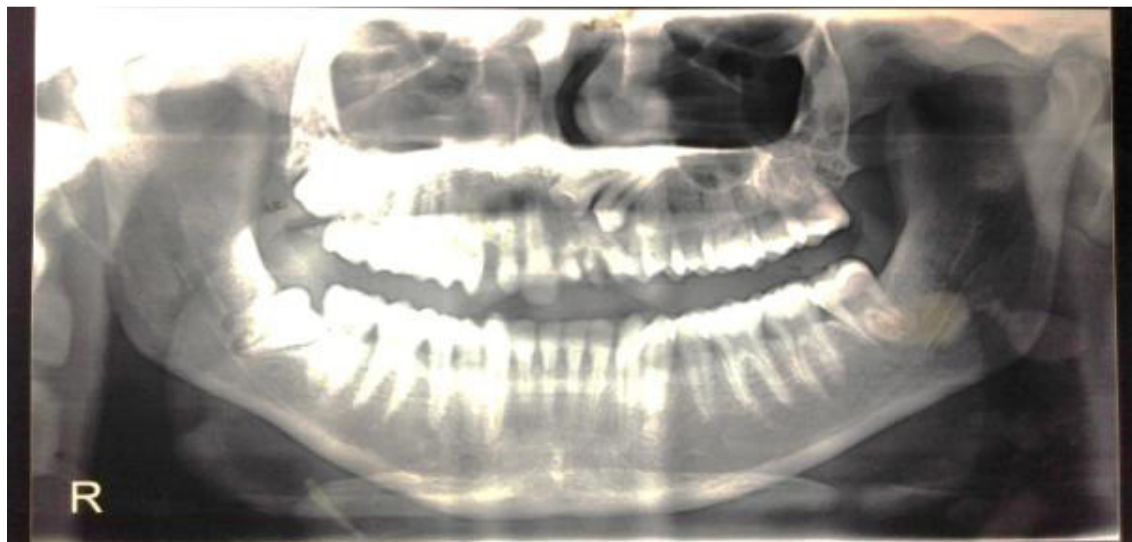
Conclusion:

This case report demonstrate a new use of combination mechanotherapy with interdisciplinary management for impaction.The condition of surrounding periodontium of impacted teeth does not depend upon type of attachment and also its placement,but it depends on type,depth, level, angulation of impaction and amount of overlying bone rather than bonding attachment on labial or palatal surface. A new functional & stable occlusion with pleasant smile was established after treatment which should also contribute to future stability.



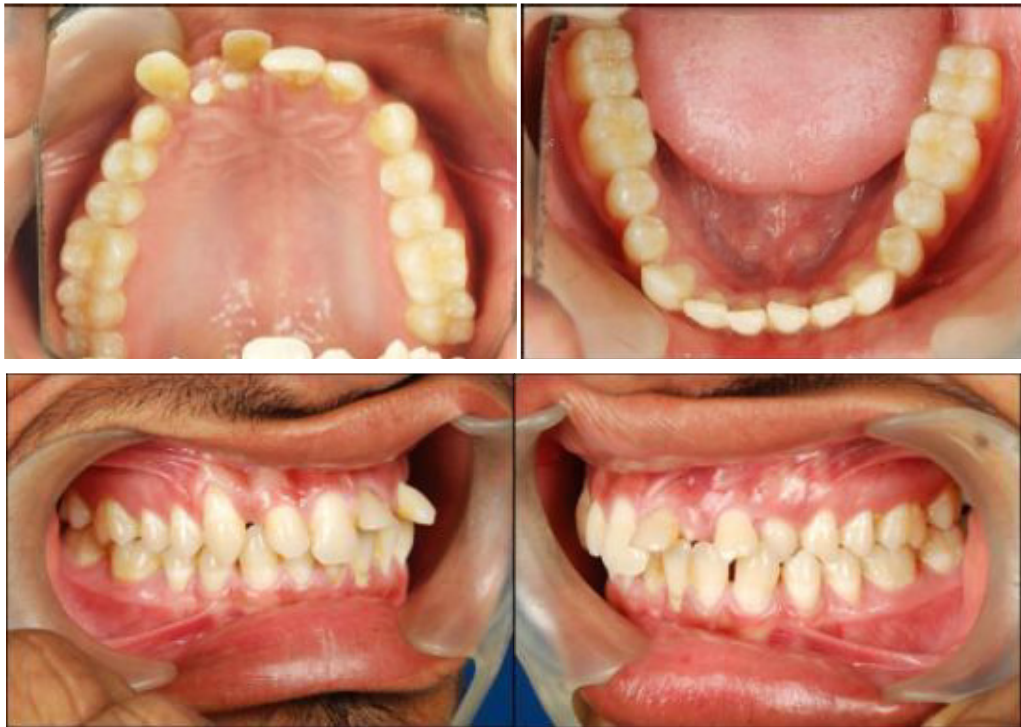

Fig 1 A: Pre-Treatment Photographs



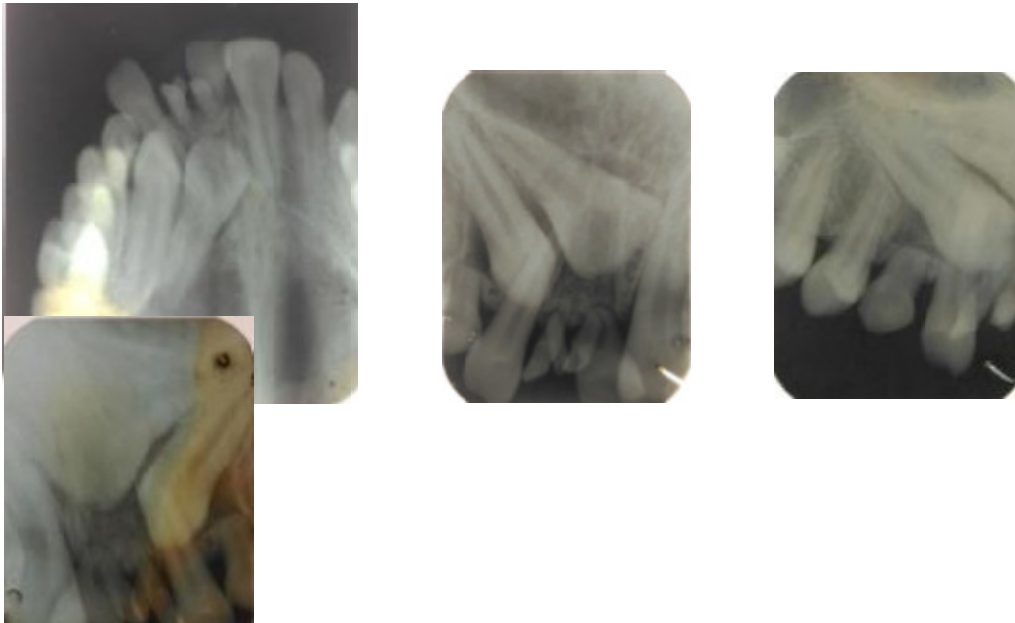
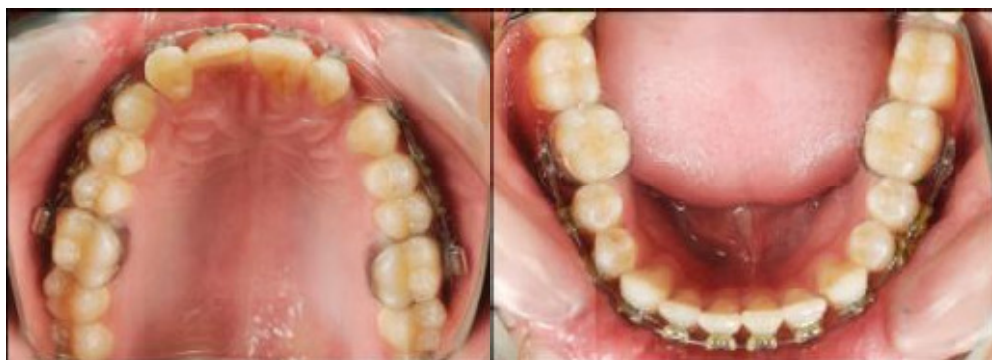
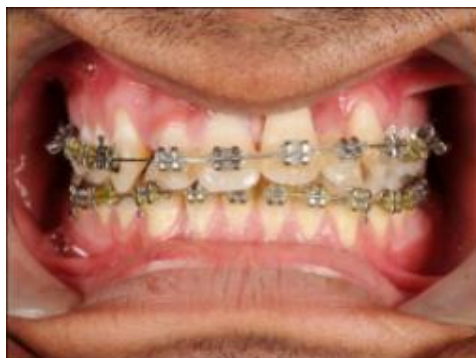
Fig 1 B: Pre-Treatment Radiographs



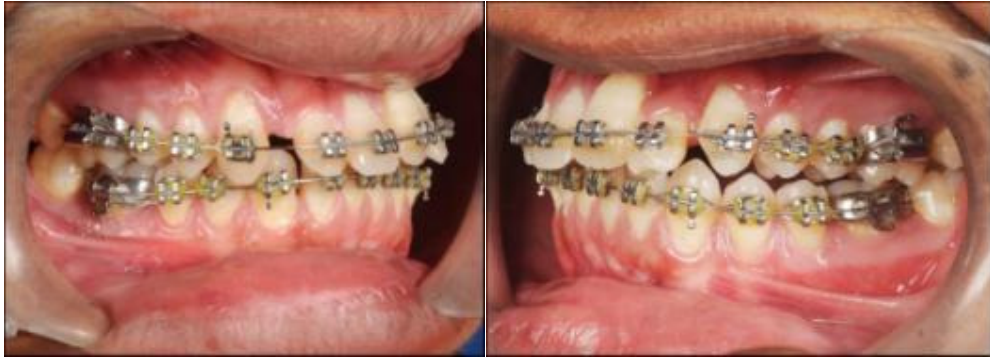

Fig 2 A : Treatment Progress Intra-Oral Photographs

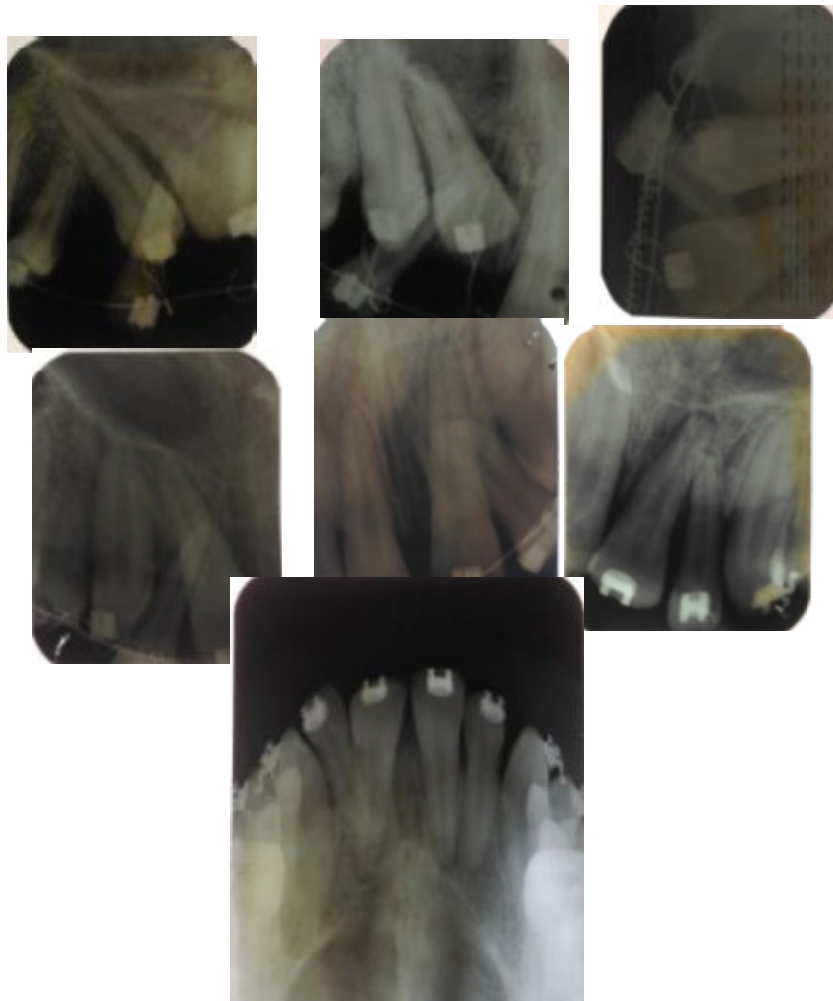

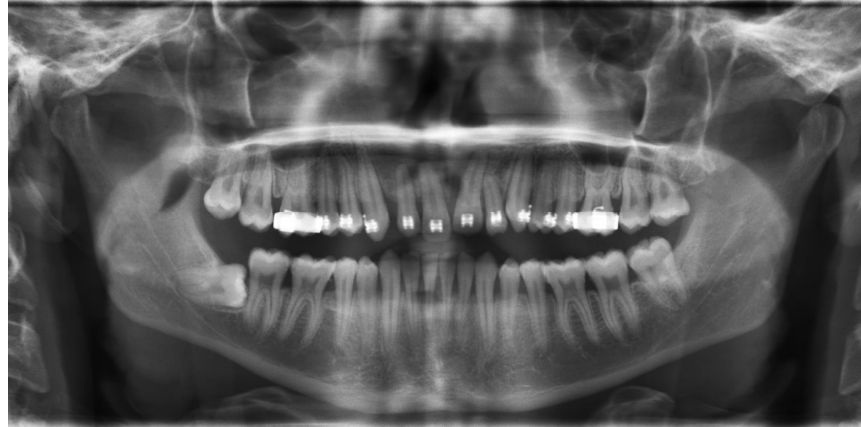


FIG 2b : Radiographs Of Treatment Progress

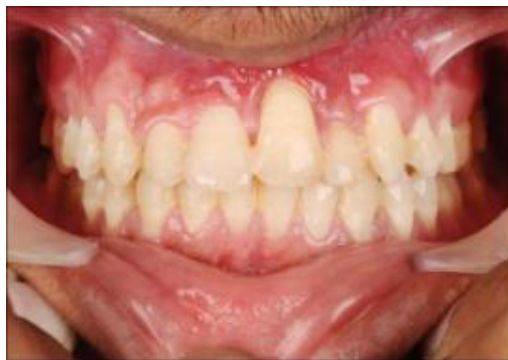

Fig 2c : Millers Class III Gingival Recession in Maxillary Central Incisor Only after 26 months of orthodontic treatment

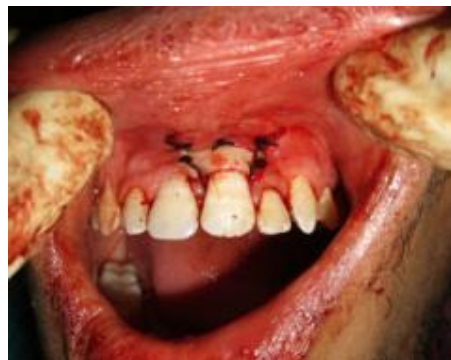
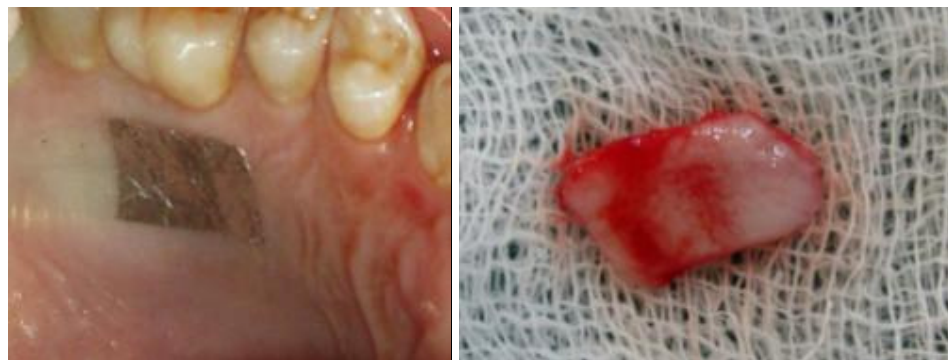
Fig 3 : Periodontal Surgery With Free Gingival Graft For Maxillary Central Incisor



Fig 4: Post-Treatment Extra-oral Photographs

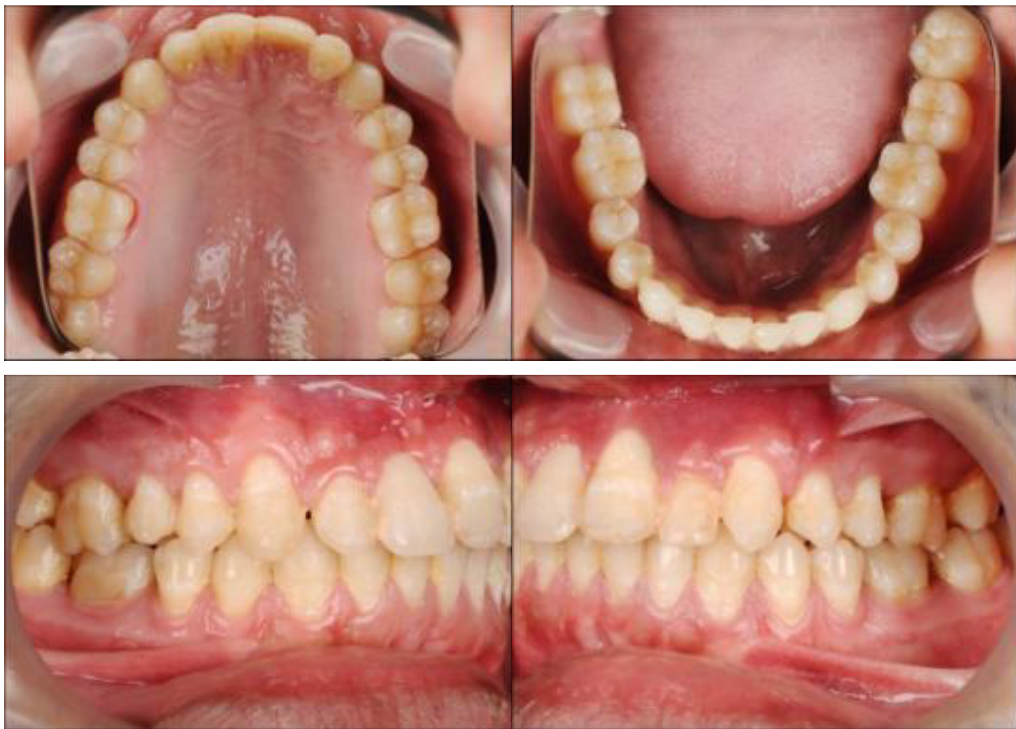
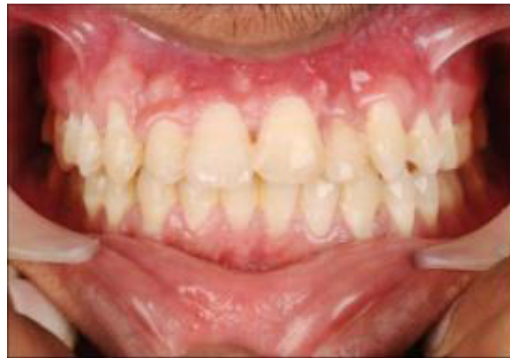
Fig 4b : Post-Treatment Intra-Oral Photographs

References:

1. Becker, A. **Orthodontic treatment of impacted teeth**. 3rd ed. Wiley Blackwell, Oxford, United Kingdom; 2012.
2. Lappin, M.M. Practical management of the impacted maxillary canine. *Am J Orthod*. 1951;37:769–778.
3. Chaushu, S., Zilberman, Y., Becker, A. Maxillary incisor impaction and its relation to canine displacement. *Am J OrthodDentofacialOrthop*. 2003;124:144–150.
4. Lappin, M.M. Practical management of the impacted maxillary canine. *Am J Orthod*. 1951;37:769–778.
5. Vanarsdall, R. and Corn, H.: Soft-tissuemanagement of labiallypositionedunerupted teeth, *Am. J. Orthod*. 72:53-64, 1977.
6. Wong-Lee, T.K., Wong, F.C. Maintaining an ideal tooth-gingiva relationship when exposing and aligning an impacted tooth. *Br J Orthod*. 1985;12:189–192.